

Noninvasive Coronary Angiography With Multislice Computed Tomography

Martin H. K. Hoffmann, MD

Heshui Shi, MD

Bernd L. Schmitz, MD

Florian T. Schmid, MD

Michael Lieberknecht, MD

Ralph Schulze, MD

Bernd Ludwig, MD

Ulf Kroschel, MD

Norbert Jahnke, MD

Winfried Haerer, MD

Hans-Juergen Brambs, MD

Andrik J. Aschoff, MD

CONVENTIONAL INVASIVE CORONARY angiography is currently the diagnostic criterion standard for clinical evaluation of known or suspected coronary artery disease (CAD). The risk of adverse events is small, but serious and potentially life-threatening sequelae may occur, including arrhythmia, stroke, coronary artery dissection, and access site bleeding (total complication rate, 1.8%; mortality rate, 0.1%).^{1,2} Furthermore, catheterization induces some discomfort and mandates routine follow-up care. Therefore, conventional invasive diagnostic angiography should be restricted to stringent clinical indications.¹ This situation constitutes the basis of the demand for a reliable gatekeeper or even noninvasive replacement.

One recently developed modality that may potentially complement invasive coronary angiography is multislice computed tomography (MSCT), which may achieve a high level of reliability and accuracy in the visualization of the coro-

For editorial comment see p 2531.

Context Multislice computed tomography (MSCT) has recently evolved as a modality for noninvasive coronary imaging.

Objective To assess the accuracy and robustness of MSCT vs the criterion standard of invasive coronary angiography for detection of obstructive coronary artery disease.

Design, Setting, and Patients Prospective, single-center study conducted in a referral center setting in Germany and enrolling 103 consecutive patients (mean age, 61.5 [SD, 9.7] years) from November 2003–August 2004 who were undergoing both invasive coronary angiography and MSCT using a scanner with 16 detector rows.

Main Outcome Measures Blinded results for both modalities compared using the patient as the primary unit of analysis, with supplementary segment- and vessel-based analyses.

Results One thousand three hundred eighty-four segments (≥ 1.5 mm diameter) were identified by invasive coronary angiography; nondiagnostic image quality of MSCT was identified for only 88 (6.4%) of these segments, mainly due to faster heart rates. Compared with invasive coronary angiography for detection of significant lesions ($>50\%$ stenosis), segment-based sensitivity, specificity, and positive and negative predictive values of MSCT were 95%, 98%, 87%, and 99%, respectively. Quantitative comparison of MSCT and invasive coronary angiography showed good correlation ($r=0.87$, $P<.001$), with MSCT systematically measuring greater-percentage stenoses (bias, +12%). In the patient-based analysis, the area under the receiver operating characteristic curve was 0.97 (95% confidence interval, 0.90–1.00), indicating high discriminative power to identify patients who might be candidates for revascularization ($>50\%$ left main artery stenosis and/or $>70\%$ stenosis in any other epicardial vessel). Threshold optimization allowed either detection of these patients with 100% sensitivity at a reasonable false-positive rate (specificity, 76.5%; MSCT stenosis, $>66\%$) or optimization of both the sensitivity and specificity ($>90\%$; MSCT stenosis, $>76\%$).

Conclusions Multislice computed tomography provides high accuracy for noninvasive detection of suspected obstructive coronary artery disease. This promising technology has potential to complement diagnostic invasive coronary angiography in routine clinical care.

JAMA. 2005;293:2471–2478

www.jama.com

nary tree.^{3–6} This modality obviates much of the risk and discomfort associated with catheterization, although it retains the risks inherent in radiation exposure and use of contrast agents.

Past studies have tested the sensitivity and specificity of MSCT vs invasive coronary angiography based on vessel segments and have suggested that MSCT is highly accurate.^{3–6} However, before routine clinical application can be advocated, it is important to evaluate predictive measures on a patient-

based level rather than simply on vessel- or segment-based levels.

One shortcoming of current cardiac computed tomography (CT) is limited temporal resolution. Recent evo-

Author Affiliations: Department of Diagnostic Radiology, University Hospital, Ulm, Germany (Drs Hoffmann, Shi, Schmitz, Schmid, Brambs, and Aschoff); and Department of Cardiology, Heart-Center, Ulm (Drs Lieberknecht, Schulze, Ludwig, Kroschel, Jahnke, and Haerer).

Corresponding Author: Martin H. K. Hoffmann, MD, Department of Diagnostic Radiology, University Hospital, Safranberg, Steinhoevelstrasse 9, D 89070 Ulm, Germany (martin.hoffmann@medizin.uni-ulm.de).

lutions of the scanner technology for MSCT imaging have made scanners with 16 detector rows widely available.⁷ These scanners allow noninvasive coverage of the coronary tree within a single breath-hold of less than 25 seconds.⁸ Coronary tree images free of motion artifacts are available only in quiescent low-motion phases of the cardiac cycle.^{6,9} The duration of these phases is inversely related to heart rate, and all studies performed to date rely on heart rate reduction induced by β -blockers.^{3-5,10} For this study we used a commercially available scanner platform that offers increased temporal resolution incorporated in a 3-dimensional volume-oriented reconstruction approach.^{6,11,12} Temporal resolution is enhanced by combining the projection data from consecutive heart cycles,^{6,11} which may overcome the need to lower heart rate to below 65/min.¹³

We therefore sought to assess the diagnostic accuracy of 16-slice MSCT scanning in a large cohort of patients with known or suspected CAD. In addition, we investigated how the newer MSCT technology performs in the setting of faster heart rate.

METHODS

Patients

From November 2003–August 2004, we enrolled 103 consecutive patients primarily with suspected CAD who were referred for conventional invasive coronary angiography. All were in sinus rhythm and able to sustain a 25-second breath-hold (tested during rehearsal on a gurney). Exclusion criteria included contraindications to iodinated contrast (ie, known allergy), renal dysfunction (serum creatinine level >1.36 mg/dL [120 μ mol/L]), hyperthyroidism (thyrotropin level <0.44 mIU/L), prior surgical revascularization, and acute coronary syndrome. The pretest probability for CAD was assessed according to American College of Cardiology/American Heart Association guidelines based on age, sex, and symptoms.¹⁴ The institutional review board of the University of Ulm approved the study, and written

informed consent was obtained from all patients.

Patients were connected to an electrocardiographic monitor prior to scan initiation, and their resting heart rate was monitored for 1 minute. If the resting heart rate during that period was 75/min or greater, intravenous metoprolol was administered up to a maximum dose of 20 mg.

Analysis Design

A qualitative evaluation was performed to assess the accuracy of MSCT to detect significant lumen narrowing (defined as $>50\%$ diameter stenosis). In addition, quantitative coronary angiography (QCA) percentage measurements were compared with stenosis measurements generated by MSCT for culprit lesions in each patient. A supplementary segment- and vessel-based evaluation was conducted for comparison with previous work. The primary unit of analysis was the patient for both qualitative and quantitative approaches. Our secondary objective was to test the dependence of coronary segment image quality on heart rate during image acquisition.

Segment- and Vessel-Based Evaluation

Imaging data were processed with observers encoding one modality blinded to the results of the other. Conventional invasive coronary angiography and MSCT images were evaluated for the occurrence of greater than 50% lumen obstruction and encoded on a segmental basis. Deviating segment assignments were settled by adjudication of a reader uninvolved in the blinded analysis. After side-by-side comparison of the modalities, this reader was allowed to reassign MSCT segment measurements to the next adjacent neighbor without crossing vessel borders (one exception was defined for the intermediate branch, which could be reclassified as both the first diagonal or the obtuse marginal branch). However, applying changes to actual stenosis readings was not permitted. Stent-bearing segments were excluded because beam-hardening arti-

facts and partial volume effects impede reliable visualization of the coronary lumen. Segments with a diameter of 1.5 mm or greater, as defined on conventional invasive angiograms by QCA, were included.

For vessel-based analyses, the segments of 1 vessel branch were combined. The coronary tree was separated into the left main artery, left anterior descending artery, left circumflex artery (LCX), and right coronary artery (RCA). Vessels with single segment exclusions were marked as excluded for vessel-based analysis. Vessels with 1 or more obstructed segments were encoded as stenotic for comparison.

Patient-Based Evaluation

Patient-based analyses were conducted in 2 ways: including all patients regardless of segment or vessel exclusions, and excluding patients with partial coronary tree coverage due to 1 or more segments with low image quality.

For both approaches, true negative was defined as correct identification by MSCT of patients without disease. True-positive readings included all patients with at least 1 matched reading in any vessel regardless of correct classification as single-vessel or multivessel disease. False-positive and false-negative classifications were defined correspondingly with stenosis detection occurring in only one modality and unmatched readings in the other. The underlying concept to be tested was that a single positive MSCT reading would require referral to invasive coronary angiography, whereas a single false-negative reading on MSCT spoiled the accuracy potential.

In addition to the qualitative analysis, a culprit lesion was defined for each patient (highest percentage obstruction on QCA). Quantitative percentage stenosis estimates of the culprit lesion generated by QCA and quantitative CT measurements were compared.

CT Imaging Protocol

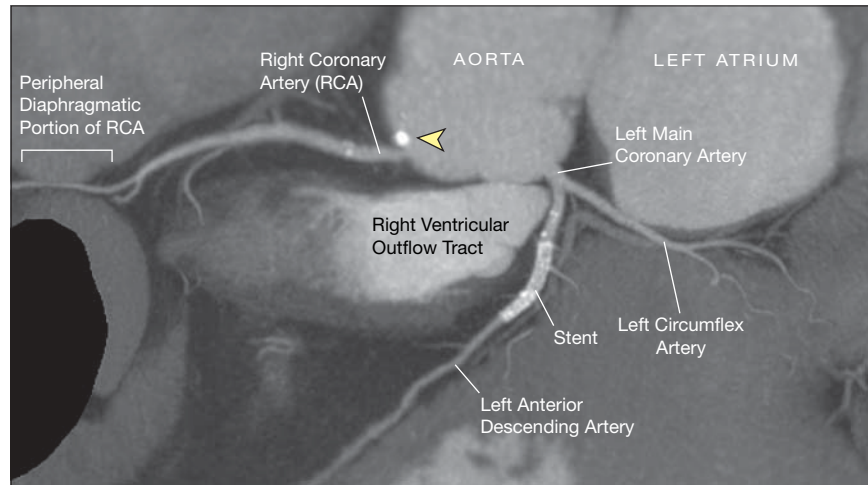
Patients were placed in a supine position for MSCT examinations using a

scanner with 16 detector rows (Brilliance 16, Philips Medical Systems, Cleveland, Ohio). Studies were preceded by scout acquisition. Test-bolus tracking was applied for precise timing of contrast injection. For acquisition of the helical scan, 1.2 mL per kg of body weight of iodinated contrast agent was administered followed by a 50-mL saline flush. The contrast flow rate was adapted according to the test-bolus acquisition (mean flow rate, 4 mL/s). An electrocardiogram was recorded during the continuous acquisition of CT data.

A 16×0.75 -mm collimation scan protocol was applied at variable pitch settings of 0.2 to 0.3 (rotation time, 420 ms). Pitch settings defined the table feed that transported patients through the gantry during helical image acquisition.^{15,16} Settings were modified according to mean heart rate over at least 10 beats directly prior to scan initiation. A pitch value of 0.2 was used for heart rate less than 65/min, 0.24 for heart rate 65/min through 74/min, and 0.3 for heart rate of 75/min or more. A tube voltage of 120 to 140 kV and a current of 190 to 300 mA were applied according to the patient's body weight. The average radiation dose applied for a typical patient was 8.1 mSv (tube current modulation off; 120 kV; 240 mA; patient weight, 75 kg; pitch, 0.2; scan length, 12 cm). Prospectively triggered x-ray tube current modulation centered around mid-diastolic cardiac cycle phases (75% of the R-R interval) was applied for all patients with a heart rate less than 65/min, resulting in a dose exposure of approximately 4.9 mSv (reduction dependent on heart rate). Depending on cardiac dimensions and pitch, the scan time varied between 16.6 and 24.5 seconds.

To obtain motion-free images, standard reconstruction windows were centered around mid-diastole (70%-80%, in 5% steps) for low heart rates (<65/min). For patients with higher heart rates (≥ 65 /min), additional reconstruction windows were centered in end-systole (45%-60%, in 5% steps). A reconstruction algorithm encompassed 3-dimen-

Figure 1. Example of Multislice Computed Tomography, Unfolded Globe View



Imaging plane is oriented along the center line of the coronary arteries and superimposed with a 4.5-mm maximum-intensity projection. Arrowhead indicates ostial calcified plaque.

sional cone-corrected back-projection in combination with adaptive multicycle enhancements of temporal resolution, as described elsewhere.^{6,11,12,17,18} All images were reconstructed using a smooth-tissue filter kernel. The best cardiac phase reconstruction for further comparative analysis was determined in a side-by-side comparison of all phases.⁶ Phase selection was performed by 2 observers in consensus attempting continuous coronary vessel delineation without any stair-step artifacts and no blurring of vessel border definition.

Each individual coronary segment was assessed for appropriate diagnostic image quality. Three types of artifacts were identified: residual motion (caused by both respiratory and cardiac motion); partial-volume averaging of high-density objects, eg, calcified coronary plaques; and faint contrast opacification. Both beam hardening and partial-volume averaging resulted in oversizing of the artifact-producing object,⁸ which may obstruct the adjacent coronary lumen and compromise assessment of lumen patency.⁸ Residual motion became apparent either as an artificial lumen obstruction, which tended to be assessed as a false-positive reading, or as blurring of the vessel borders, which may prevent

plaque detection, thereby resulting in false-negative readings.

Reading of MSCT images was conducted on maximum-intensity projections oriented in multiple viewing directions. They were supplemented by volume renderings and curved multiplanar reformation images with a center line threaded through the coronary arteries (FIGURE 1). Electronic calipers were used to measure coronary lumen diameter, which allowed percentage quantification of obstructive lesions according to the same standards as those applied in QCA.¹⁹

Coronary Angiography

Conventional selective invasive coronary angiography images were acquired using standard techniques. The mean (SD) interval between the MSCT scan and conventional coronary angiography was 16.3 (15.1) days. Coronary arteries were divided into segments according to American Heart Association classifications.²⁰ Angiograms were evaluated by 2 readers blinded to the results of MSCT imaging. The percentage of lumen reduction of stenotic lesion sites was quantified using standard QCAPlus version 03.10.30 (Sanders Data Systems, Palo Alto, Calif).

Statistical Analysis

Sample size was determined by power analysis for a single proportion.²¹ We hypothesized that MSCT should detect greater than 50% lumen narrowing, with a sensitivity of 80% or greater. The sample size was calculated for a power level of greater than 90%, an α error of .05, and an expected sensitivity of 92% or greater based on previous reports.

Accuracy parameters are presented with 95% confidence intervals (CIs) based on binomial distributions. Quantitative percentage stenosis gradings were compared using Pearson correlation and Bland-Altman plots.²² The area under the receiver operating characteristic (ROC) curve (AUC) was calculated for MSCT to detect obstructive lesions.²³ Calculation was conducted at various thresholds defined by QCA (50%, 60%, and 70%). A QCA threshold that might indicate need for revascularization was defined as left main artery stenosis greater than 50%, lesions greater than 70% of any other epicardial vessel, or both. The corresponding ROC analysis was conducted for the whole group as

well as for the subgroup of patients who were primarily evaluated for suspected CAD. The AUC values for both analyses were compared to rule out substantial confounding effects induced by the inclusion of patients who had undergone percutaneous coronary intervention. The ROC curves were used to optimize the CT thresholds for highest sensitivity and optimal values of both accuracy parameters.

The association between heart rate and image quality was evaluated by comparing segment inclusion rates after stratification over increasing heart rate in 4 different groups. The segment inclusion rate within the 4 groups was compared using a 2-tailed χ^2 test. Statistics were computed using SAS version 9.1 (SAS Institute Inc, Cary, NC) and Excel-based ROC tools (Acomed, Leipzig, Germany).

RESULTS

A total of 128 patients were evaluated for enrollment; patients with a postsurgical revascularization status ($n=17$), multiple premature ventricular contractions ($n=2$), inability to sustain a 25-second breath-hold ($n=2$), known allergy to iodinated contrast agents ($n=3$), and hyperthyroidism ($n=1$) were excluded. For the final sample size ($N=103$), the achieved power was 93.2%. Characteristics of enrolled patients are summarized in TABLE 1.

The mean (SD) heart rate during scanning was 68.7 (11.6)/min (range, 45-111/min). Prospectively triggered tube current modulation was applied in 46 patients (44.7%).

Segment adjudication was applied for 23 (22%) of the patients (descending

RCA, $n=9$; intermediate branch, $n=7$; LCX branches, $n=5$; left anterior descending branches, $n=2$). Unresolved cases were either counted in the appropriate false-positive or false-negative categories (following sections), prospectively excluded due to low image quality on MSCT analysis, or excluded due to failing standard of reference for patients with coronary anomalies ($n=3$). For the latter, insufficient contrast opacification due to failed selective cannulation was apparent on invasive coronary angiography films (RCA, $n=2$; LCX, $n=1$). Disease prevalence identified by invasive coronary angiography (stenosis $>50\%$) was 56% (58/103).

Segment- and Vessel-Based Evaluation

One thousand three hundred eighty-four segments, each with a diameter of 1.5 mm or greater, were identified, resulting in 13.4 (SD, 2.2) segments for analysis per patient. Nondiagnostic image quality was identified in 88 (6.4%) of these segments, with image quality compromised by residual motion artifacts in the majority of cases (60 [68%]). Extensive coronary wall calcifications (17 [19%]) and low-vessel lumen opacifications (11 [13%]) were less apparent in this group. Motion artifacts were most frequently located in the mid RCA ($n=34$) and increased significantly at higher heart rates (TABLE 2). Five segments deemed not assessable by MSCT (severe calcifications [$n=4$] or motion artifacts [$n=1$, proximal RCA]) showed significant obstructions on invasive coronary angiography films. These segments were prospectively judged not assessable and hence these patients were excluded without corruption of the potential accuracy of MSCT. Parameters calculated on a segmental basis are shown in TABLE 3. A sample case without stenosis is presented in FIGURE 2. Cases with matched positive readings are presented in FIGURE 3.

Eight segments were classified as false-negative. They were located in the LCX ($n=5$) or its side branches ($n=2$). A false-negative reading located in the

Table 1. Patient Characteristics (N = 103)

| Characteristic | No. (%) |
|--------------------------------------|------------|
| Age, mean (SD), y | 61.5 (9.7) |
| Men | 71 (69) |
| Primary evaluation for suspected CAD | 91 (88) |
| Recurrent symptoms after PCI | 12 (12) |
| BMI, mean (SD)* | 26.5 (3.7) |
| Pretest probability for CAD† | |
| Low | 2 (2) |
| Intermediate | 65 (63) |
| High | 36 (35) |

Abbreviations: BMI, body mass index; CAD, coronary artery disease; PCI, percutaneous coronary intervention. *Calculated as weight in kilograms divided by square of height in meters.

†Assessed considering age, sex, and symptoms in accordance with American College of Cardiology/American Heart Association guidelines.¹⁴

Table 2. Relationship of Heart Rate and Segment (Vessel) Assessment by Multislice Computed Tomography

| Assessment Level | No./Total (%) | | | | Total |
|------------------|-----------------------|--------------|---------------|---------------|----------------|
| | Heart Rate, beats/min | | | | |
| | <60 | 60-70 | 71-80 | >80 | |
| Segments | 295/302 (98) | 530/549 (97) | 335/374 (90)* | 136/159 (85)* | 1296/1384 (93) |
| Vessels | 81/88 (92) | 143/159 (90) | 85/109 (78)* | 36/47 (77)* | 345/403 (86) |
| Patients | 18/22 (82) | 30/41 (73) | 19/28 (68) | 8/12 (67) | 75/103 (73) |

*Statistically significant differences detected vs groups with heart rate ≤ 70 beats/min ($P < .01$ by χ^2 test). No significant differences were apparent for the patient groups.

Table 3. Diagnostic Accuracy of MSCT to Detect Stenoses of >50% Lumen Diameter Reduction

| | Lesions (Segments) | Vessels | Patients* | Patients† |
|---|----------------------------|--------------------------|------------------------|------------------------|
| Stenoses by QCA, No. | 157 | 95 | 57 | 44 |
| Stenoses by MSCT, No. | 149 | 92 | 55 | 42 |
| False-positive, No. | 22 | 9 | 6 | 1 |
| False-negative, No. | 8 | 3 | 2 | 2 |
| Diagnostic Accuracy of MSCT, No./Total (% [95% CI]) | | | | |
| Sensitivity | 149/157 (95 [90.2-97.8]) | 92/95 (97 [91.1-99.3]) | 55/57 (97 [87.9-99.6]) | 42/43 (95 [84.5-99.4]) |
| Specificity | 1117/1139 (98 [96.9-98.6]) | 241/250 (96 [93.3-98.3]) | 38/45 (87 [73.7-95.1]) | 28/30 (97 [83.3-99.9]) |
| Positive predictive value | 149/171 (87 [85.9-89.6]) | 92/101 (91 [83.8-95.8]) | 56/63 (90 [79.8-96.3]) | 43/45 (98 [87.7-99.9]) |
| Negative predictive value | 1117/1125 (99 [98.6-99.7]) | 241/244 (99 [96.5-99.8]) | 40/42 (95 [83.8-99.4]) | 30/32 (94 [79.2-99.2]) |

Abbreviations: CI, confidence interval; MSCT, multislice computed tomography; QCA, quantitative coronary angiography.

*Including all patients for the analysis.

†Excluding 28 of 103 patients (27%) with only partial coronary tree coverage available.

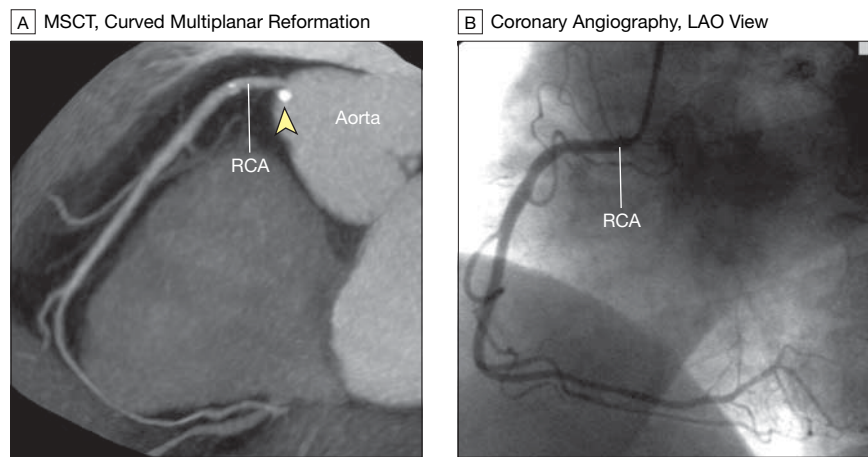
posterior descending artery (n=1) was related to insufficient contrast opacification.

A total of 22 false-positive classifications occurred. They were related to severe vessel wall calcifications (n=7) and residual motion (n=15 [mid-RCA, n=12; LCX, n=3]). For the lesions with vessel wall calcifications, conventional invasive angiography revealed only minor wall irregularities or insignificant indentations (FIGURE 4).

The accuracy parameters for vessel-based evaluation are summarized in Table 3. All significant left main coronary artery obstructions (n=4) were correctly identified by MSCT. All vessel occlusions (n=21) were correctly detected on MSCT scans. Fifty-eight of the 403 assessable vessels (14.4%) had partial segments excluded due to artifacts (Tables 2 and 3).

Patient-Based Evaluation

The accuracy parameters for patient-based evaluation are summarized in Table 3. Excluding the 28 patients (27%) with partial coronary tree coverage improved specificity. Multislice CT correctly identified 38 of the 45 patients (84%) without significant stenoses demonstrated by conventional invasive angiography. Two of 58 patients with CAD (3.4%) were not detected by MSCT. One proximal lesion in the posterior descending artery and 1 diagonal branch lesion were missed by MSCT due to inadequate opacification. Patients with single-vessel disease demonstrated by in-

Figure 2. Sample Case in Individual With Nonstenosed Coronary Artery: Matched Negative Readings

A 74-year-old woman referred for multislice computed tomography (MSCT) 3 years after percutaneous coronary intervention with stent placement in the proximal left anterior descending artery. The stent segment was primarily excluded from further analysis and does not appear here. A, Curved multiplanar reformation image along the right coronary artery (RCA). Ostial calcified plaque (arrowhead) does not induce lumen narrowing. B, Conventional invasive coronary angiogram confirms that no high-grade lesions are discernible. The angiogram shows more side branches compared with tomography, due to both higher in-plane spatial resolution and a more comprehensive projection. LAO indicates left anterior oblique.

vasive coronary angiography (n=22) were either correctly classified (15 [68%]) by MSCT or were misclassified as having multivessel disease (5 [23%]). Thirty patients with multivessel disease were correctly classified by MSCT, while the remaining 6 were classified as having single-vessel disease.

Quantitative comparison of stenosis grading using MSCT and invasive coronary angiography showed good correlation ($r=0.87$, $P<.001$). Bland-Altman analysis revealed that CT measured a greater percentage of stenoses

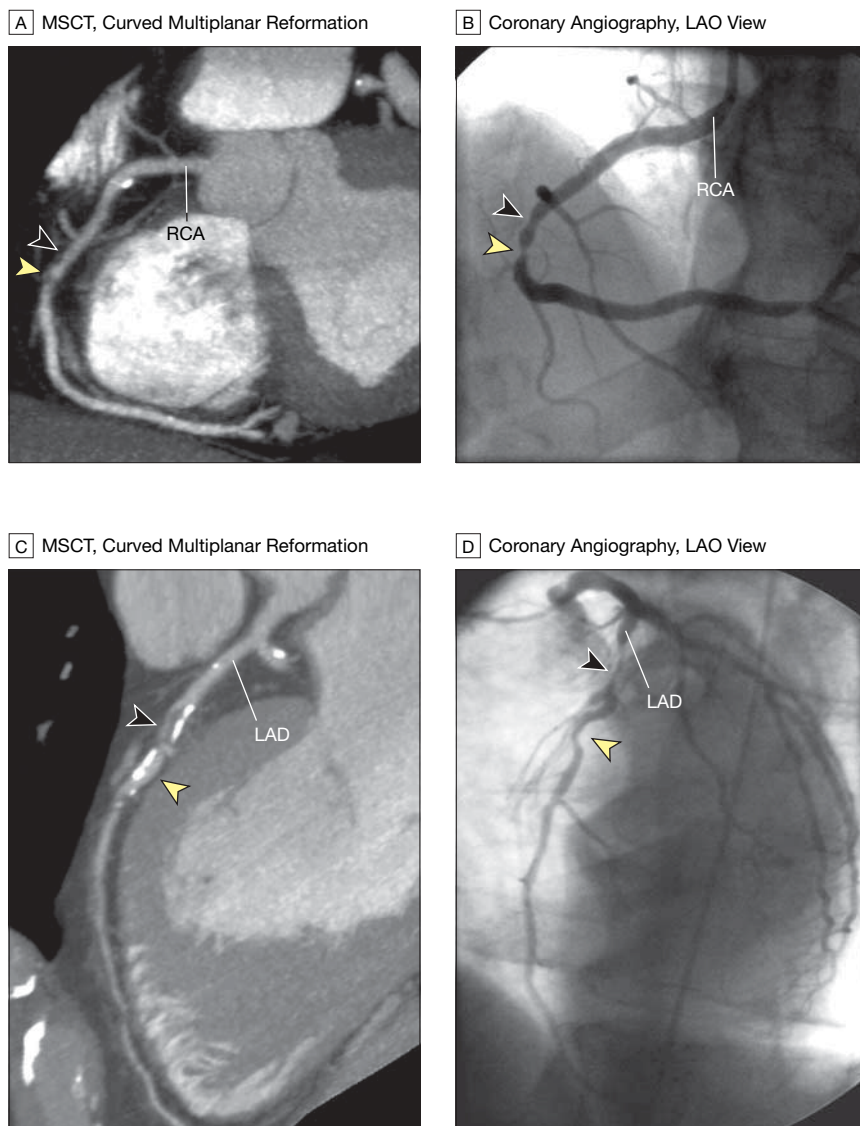
(bias, +12%; limits of agreement, -19% to +43%) (FIGURE 5). The AUC for identification of patients with stenoses eligible for revascularization was 0.97 (95% CI, 0.91-1.00; complete study cohort). Conducting the same analysis after exclusion of patients who had undergone percutaneous coronary intervention rendered the same AUC value of 0.97, with minimal widening of the confidence bounds (95% CI, 0.90-1.00). Applying QCA stenosis thresholds of greater than 50%, greater than 60%, and greater than 70%

resulted in AUC values of 0.97 (95% CI, 0.91-0.99), 0.92 (95% CI, 0.84-0.96), and 0.97 (95% CI, 0.92-1.00), respectively. Threshold optimization for iden-

tifying patients appropriate for revascularization occurred at greater than 66% of MSCT stenosis quantification (100% sensitivity, 76.5% specificity).

Optimization of both parameters occurred at greater than 76% MSCT stenosis grading (91.4% sensitivity, 91.2% specificity).

Figure 3. Sample Cases in Individuals With Stenosed Coronary Arteries: Matched Positive Readings



A, Multislice computed tomography (MSCT) in a 62-year-old man referred for MSCT for suspected coronary artery disease. The MSCT image renders corresponding lesion sites discernible (arrowheads correspond to locations in panel B). In addition, the MSCT image shows soft plaques (ie, dark, hypodense areas reflecting lipid or fibrous composition) causing both the indentation and the stenotic lumen narrowing. B, Conventional invasive coronary angiogram showing high-grade stenosis (yellow arrowhead) in the descending portion of the right coronary artery (RCA), preceded by an indentation (black arrowhead) that supposedly is plaque-related. C, MSCT in a 61-year-old man referred for MSCT imaging for suspected coronary artery disease. The MSCT image shows that the lumen obstruction in the left anterior descending (LAD) artery is caused by fibrocalcific plaque (black arrowhead) with an inner fibrotic (hypodense) and an outer calcific (hyperdense) layer. The indentation as shown in panel D is caused by calcified plaque (yellow arrowhead). D, Conventional invasive coronary angiogram showing high-grade lumen narrowing in the proximal LAD (black arrowhead). After the branching point of the first septal perforator, another indentation (yellow arrowhead) is discernible. LAO indicates left anterior oblique.

COMMENT

We found that, compared with invasive coronary angiography, MSCT has a high discriminative power to detect obstructive CAD. This is not only shown for the detection of the standard definition of significant disease, defined as greater than 50% lumen narrowing of the coronary artery,² but also at other thresholds. The discriminative power of MSCT is high for identification of patients who are appropriate candidates for revascularization, ie, those with greater than 50% left main artery disease, greater than 70% stenosis in other epicardial vessels, or both. Threshold optimization showed that MSCT could detect these patients either with 100% sensitivity, at a false-positive rate still within reasonable limits, or that both sensitivity and specificity could be optimized beyond 90%.

Correlation of the percentage of lumen quantification for MSCT and QCA was high, with MSCT systematically suggesting higher values. While the limits of agreement for this comparison appeared high at first consideration (−20% to 40%), they must be seen in perspective with the intramodality variability of invasive coronary angiography (−15% to 21%).¹⁹

Because ROC analysis is independent of disease prevalence,²³ results generated for our study cohort with an intermediate to high prevalence of disease may well be applicable to lower-risk populations. Therefore, MSCT using scanners with 16 detector rows has the potential to be routinely applied for identifying patients who, while suspect, are unlikely to have clinically significant disease. Our findings are consistent with multiple single-center studies showing consistently high accuracy and negative predictive values.^{3-5,10,24} The indication is limited by false-positive rates that consecutively reduce specificity and positive predictive value.

Multislice CT has the potential to become a valuable complement to invasive diagnostic angiography, but ideally a reliable visualization of the complete coronary tree is required. While only 6.4% of the coronary segments showed low diagnostic image quality, consistent with findings from other studies (6.6%,²⁴ 7%³), segmental exclusion rates are based on clustered evaluations.²³ Segment-based exclusions due to low image quality correlated with 14% and 27% exclusion rates on vessel- and patient-based levels. Arguably only the patient-based level is clinically relevant. Because diagnostic decisions based on MSCT were derived from incomplete coronary tree coverage in 27% of our patients, this technology is not yet ready to challenge invasive coronary angiography as a true alternative. However, if the results generated with prior generations of CT scanners (4 detector rows, 32% exclusion rate²⁶) are extrapolated beyond the current generation (16 detector rows, 7% exclusion rate) to the scanner generation that is currently being introduced for clinical evaluation (up to 64 detector rows), reliability may increase very rapidly in the near future. The striking relationship of the number of detector rows to the reliability of image quality conveys a simplification that does not account for very important technical aspects of cardiac CT imaging.

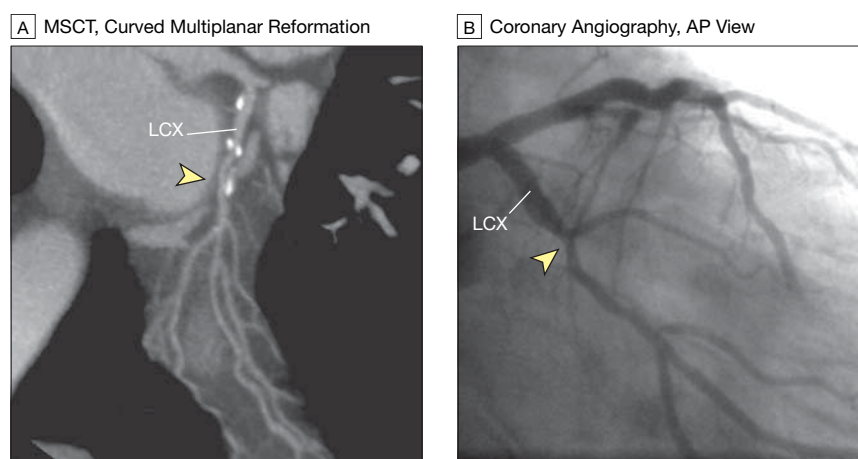
Clinical data show that the standard currently available temporal resolution is not sufficient to cover the normal range of resting heart rates.^{6,13,27} This deficiency is corrected with β -blocker-induced heart rate reduction,^{13,27} which prolongs diastole and extends the phases of low cardiac and subsequent coronary motion to allow artifact-free imaging.^{6,28} Two strategies have emerged to increase temporal resolution. The first strategy is based on faster gantry rotation. The reconstruction of 1 CT frame depends on a 180° turn of the gantry; thus, temporal resolution increases linearly with shortening of the gantry rotation times.²⁹ The second strategy, supported by our current data, is based on

shortening the reconstruction window within a single heart cycle by segmenting the acquisition of image data over multiple heartbeats.¹² An adaptive multicycle reconstruction approach combines data from consecutive cardiac cycles and enhances temporal resolution to an average of 140 ms.^{6,11}

Spatial resolution of MSCT is now in the submillimeter range but still does not match that of invasive coronary angiography.³⁰ This study shows a reasonable correlation of quantitative mea-

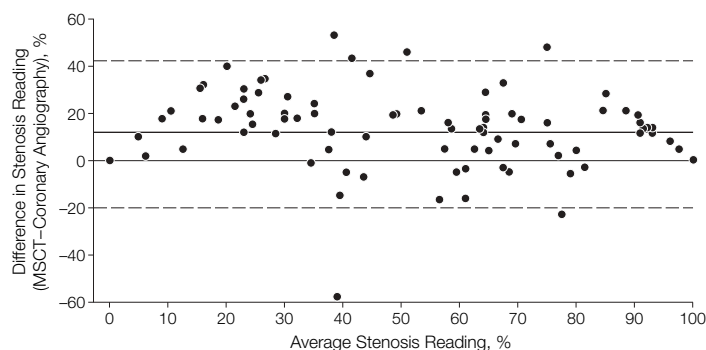
asures acquired with the 2 modalities. Further improvements are needed for accurate delineation of the coronary lumen adjacent to high-density objects such as calcified plaque or stent struts.²⁶ Such high-density objects extend beyond their true size into neighboring volume voxels on MSCT images. This problem may be alleviated by decreasing voxel size or increasing spatial resolution. However, with detector technology currently available, spatial resolution is dose-limited. Increasing

Figure 4. Sample Case in Individual With Stenosed Coronary Artery: False-Positive Reading



A, Multislice computed tomography (MSCT) in a 68-year-old man referred for MSCT imaging for suspected coronary artery disease. The MSCT findings represent a typical false-positive reading. Specifically, the MSCT image shows plaque located on the main left circumflex artery (LCX; arrowhead) in the atrioventricular groove. Subjective and objective assessment identified significant lumen narrowing. B, Conventional invasive coronary angiogram showing the lumen indentation caused by plaque impingement (arrowhead). However, quantitative coronary angiography did not identify significant (>50%) lumen narrowing. AP indicates anterior-posterior.

Figure 5. Bland-Altman Analysis of Stenosis Grading Using Multislice Computed Tomography (MSCT) vs Conventional Invasive Coronary Angiography



Dashed lines indicate 95% confidence limits; bold line, bias.

spatial resolution requires multiplication of the radiation dose by a power of 4 to keep image noise constant.³¹

In conclusion, we found that MSCT shows reasonably high accuracy for detecting significant obstructive CAD when assessed at a patient level. At its current stage of development, it may therefore be used to substantially reduce likelihood of clinically important CAD in patients with suspected disease. The appeal of MSCT compared with conventional coronary angiography is that it is noninvasive, avoiding most catheter-associated risks and discomforts with the exception of expo-

sure to iodinated contrast agents and radiation. With rapidly improving technology, MSCT may well evolve from a useful complement to invasive angiography to a clinically viable alternative.³²

Author Contributions: Dr Hoffmann had full access to all of the data in the study and takes responsibility for the integrity of the data and the accuracy of the data analysis.

Study concept and design: Hoffman, Schmitz, Haerer, Brambs.

Acquisition of data: Hoffman, Shi, Schmid, Lieberknecht, Schulze, Ludwig, Kroschel, Jahnke, Haerer.

Analysis and interpretation of data: Hoffman, Shi, Lieberknecht, Schulze, Ludwig, Kroschel, Jahnke, Haerer, Aschoff.

Drafting of the manuscript: Hoffman, Shi, Schmid, Aschoff.

Critical revision of the manuscript for important intellectual content: Hoffman, Schmitz, Lieberknecht, Schulze, Ludwig, Kroschel, Jahnke, Haerer, Brambs.

Statistical analysis: Hoffman, Shi, Lieberknecht.

Obtained funding: Brambs.

Administrative, technical, or material support: Hoffman, Schmid, Lieberknecht, Haerer, Aschoff.

Study supervision: Hoffman, Lieberknecht, Aschoff.

Financial Disclosures: None reported.

Funding/Support: This study was funded by the State Government of Baden-Wuerttemberg, Germany. The computed tomography equipment was partially provided by Philips Medical Systems, Best, the Netherlands, on the basis of a beta-site contract.

Role of Sponsor: Neither the State Government of Baden-Wuerttemberg nor Philips Medical Systems had any involvement in the design or conduct of this study; data management and analysis; or manuscript preparation and review or authorization for submission.

Acknowledgment: We thank Bonnie Hami, MA, of the Department of Radiology, University Hospitals of Cleveland, Cleveland, Ohio, for her editorial assistance in the preparation of the manuscript.

REFERENCES

- Scanlon P, Faxon D, Audet A, et al; Society for Cardiac Angiography and Interventions. ACC/AHA guidelines for coronary angiography: a report of the American College of Cardiology/American Heart Association Task Force on practice guidelines (Committee on Coronary Angiography). *J Am Coll Cardiol*. 1999;33:1756-1824.
- Bashore TM, Bates ER, Berger PB, et al. American College of Cardiology/Society for Cardiac Angiography and Interventions Clinical Expert Consensus Document on cardiac catheterization laboratory standards: a report of the American College of Cardiology Task Force on Clinical Expert Consensus Documents. *J Am Coll Cardiol*. 2001;37:2170-2214.
- Mollet N, Cademartiri F, Nieman K, et al. Multislice spiral computed tomography coronary angiography in patients with stable angina pectoris. *J Am Coll Cardiol*. 2004;43:2265-2270.
- Nieman K, Cademartiri F, Lemos PA, Raaijmakers R, Pattynama PM, de Feyter PJ. Reliable noninvasive coronary angiography with fast submillimeter multislice spiral computed tomography. *Circulation*. 2002;106:2051-2054.
- Ropers D, Baum U, Pohle K, et al. Detection of coronary artery stenoses with thin-slice multi-detector row spiral computed tomography and multiplanar reconstruction. *Circulation*. 2003;107:664-666.
- Hoffmann MH, Shi H, Manzke R, et al. Noninvasive coronary angiography with 16-detector row CT: effect of heart rate. *Radiology*. 2005;234:86-97.
- Schoenhagen P, Halliburton SS, Stillman AE, et al. Noninvasive imaging of coronary arteries: current and future role of multi-detector row CT. *Radiology*. 2004;232:7-17.
- Schoepf UJ, Becker CR, Ohnesorge BM, Yucel EK. CT of coronary artery disease. *Radiology*. 2004;232:18-37.
- Manzke R, Koehler T, Nielsen T, Hawkes D, Grass M. Automatic phase determination for retrospectively gated cardiac CT. *Med Phys*. 2004;31:3345-3362.
- Mollet NR, Cademartiri F, Krestin GP, et al. Improved diagnostic accuracy with 16-row multi-slice computed tomography coronary angiography. *J Am Coll Cardiol*. 2005;45:128-132.
- Manzke R, Grass M, Nielsen T, Shechter G, Hawkes D. Adaptive temporal resolution optimization in helical cardiac cone beam CT reconstruction. *Med Phys*. 2003;30:3072-3080.
- Grass M, Manzke R, Nielsen T, et al. Helical cardiac cone beam reconstruction using retrospective ECG gating. *Phys Med Biol*. 2003;48:3069-3084.
- Giesler T, Baum U, Ropers D, et al. Noninvasive visualization of coronary arteries using contrast-enhanced multidetector CT: influence of heart rate on image quality and stenosis detection. *AJR Am J Roentgenol*. 2002;179:911-916.
- Gibbons RJ, Balady GJ, Bricker JT, et al; American College of Cardiology/American Heart Association Task Force on Pediatric Guidelines (Committee to Update the 1997 Exercise Testing Guidelines). ACC/AHA 2002 guideline update for exercise testing; summary article: a report of the American College of Cardiology/American Heart Association Task Force on Pediatric Guidelines (Committee to Update the 1997 Exercise Testing Guidelines). *Circulation*. 2002;106:1883-1892.
- Manzke R, Grass M, Hawkes D. Artifact analysis and reconstruction improvement in helical cardiac cone beam CT. *IEEE Trans Med Imaging*. 2004;23:1150-1164.
- Ohnesorge BM, Becker CR, Flohr TG, Reiser MF. *Multi-Slice CT in Cardiac Imaging*. New York, NY: Springer; 2002.
- Hoffmann MH, Shi H, Schmid FT, Gelman H, Brambs H-J, Aschoff AJ. Noninvasive coronary imaging with MDCT in comparison to invasive conventional coronary angiography: a fast-developing technology. *AJR Am J Roentgenol*. 2004;182:601-608.
- Shechter G, Naveh G, Altman A, Proksa R, Grass M. Cardiac image reconstruction on a 16-slice CT scanner using a retrospectively ECG-gated, multi-cycle 3D back-projection algorithm. *Proc SPIE*. 2003;5032:1820-1828.
- Uehata A, Matsuguchi T, Bittl JA, et al. Accuracy of electronic digital calipers compared with quantitative angiography in measuring coronary arterial diameter. *Circulation*. 1993;88:1724-1729.
- Austen W, Edwards J, Frye R, et al. A reporting system on patients evaluated for coronary artery disease: report of the Ad Hoc Committee for Grading of Coronary Artery Disease, Council on Cardiovascular Surgery, American Heart Association. *Circulation*. 1975;51:5-40.
- Lenth RV. Some practical guidelines for effective sample size determination. *Am Stat*. 2001;55:187-193.
- Bland J, Altman D. Comparing methods of measurement: why plotting difference against standard method is misleading. *Lancet*. 1995;346:1085-1087.
- Obuchowski NA. ROC analysis. *AJR Am J Roentgenol*. 2005;184:364-372.
- Kuettner A, Beck T, Drosch T, et al. Diagnostic accuracy of noninvasive coronary imaging using 16-detector slice spiral computed tomography with 188 ms temporal resolution. *J Am Coll Cardiol*. 2005;45:123-127.
- Gonen M, Panageas KS, Larson SM. Statistical issues in analysis of diagnostic imaging experiments with multiple observations per patient. *Radiology*. 2001;221:763-767.
- Achenbach S. Detection of coronary stenoses by multidetector computed tomography: it's all about resolution. *J Am Coll Cardiol*. 2004;43:840-841.
- Schroeder S, Kopp AF, Kuettner A, et al. Influence of heart rate on vessel visibility in noninvasive coronary angiography using new multislice computed tomography: experience in 94 patients. *Clin Imaging*. 2002;26:106-111.
- Lewis RP, Rittogers SE, Froester WF, Boudoulas H. A critical review of the systolic time intervals. *Circulation*. 1977;56:146-158.
- Flohr T, Ohnesorge B. Heart rate adaptive optimization of spatial and temporal resolution for electrocardiogram-gated multislice spiral CT of the heart. *J Comput Assist Tomogr*. 2001;25:907-923.
- Pannu HK, Flohr TG, Corl FM, Fishman EK. Current concepts in multi-detector row CT evaluation of the coronary arteries: principles, techniques, and anatomy. *Radiographics*. 2003;23:S111-S125.
- Prokop M. Multislice CT: technical principles and future trends. *Eur Radiol*. 2003;13(suppl 5):M3-M13.
- de Feyter PJ, Nieman K. Noninvasive multi-slice computed tomography coronary angiography: an emerging clinical modality. *J Am Coll Cardiol*. 2004;44:1238-1240.

men determine the right thing to do if they develop prostate cancer.

Peter C. Albertsen, MD, MS
albertsen@nso.uchc.edu
University of Connecticut Health Center
Farmington

James A. Hanley, PhD
McGill University
Montreal, Quebec

Judith Fine, BA
University of Connecticut
Farmington

Financial Disclosures: None reported.

1. Gleason DF, Mellinger GT; Veterans Administration Cooperative Urological Research Group. Prediction of prognosis for prostatic adenocarcinoma by combined histological grading and clinical staging. *J Urol.* 1974;111:58-64.
2. Humphrey PA, Walther PJ, Currin SM, Vollmer RT. Histologic grade, DNA ploidy and intraglandular tumor extent as indicators of tumor progression of clinical stage B prostatic carcinoma: a direct comparison. *Am J Surg Pathol.* 1991;15:1165-1170.
3. Chin JL, Reiter RE. Molecular markers and prostate cancer prognosis. *Clin Prostate Cancer.* 2004;3:157-164.
4. Albertsen PC, Hanley JA, Penson DF, Barrows GH, Fine J. Prostate cancer and the Will Rogers phenomenon. *J Urol.* 2005;173:253.
5. Thompson IM, Pauler DK, Goodman PJ, et al. Prevalence of prostate cancer among men with a prostate specific antigen level of < 4.0 ng per milliliter. *N Engl J Med.* 2004;350:2239-2246.

CORRECTIONS

Omitted Author Degree: In the Original Contribution entitled "Acute Illnesses Associated With Pesticide Exposure at Schools" published in the July 27, 2005, issue of *JAMA* (2005;294:455-465), an author's second degree was missing in the byline. The byline should have read Alan Becker, MPH, PhD.

Incorrect Data in Table: In the Original Contribution entitled "Noninvasive Coronary Angiography With Multislice Computed Tomography" published in the May 25, 2005, issue of *JAMA* (2005;293:2471-2478), the data in the last 2 columns of **TABLE 3** on page 2475 were incorrect. These data should have read as follows:

Table 3. Diagnostic Accuracy of MSCT to Detect Stenoses of >50% Lumen Diameter Reduction

| Patients* | Patients† |
|------------------------|-----------------------|
| 58 | 45 |
| 56 | 43 |
| 7 | 2 |
| 2 | 2 |
| 56/58 (96 [88.1-99.6]) | 43/45 (95 [89.5-100]) |
| 38/45 (84 [70.6-93.5]) | 28/30 (93 [84.4-100]) |
| 56/63 (89 [78.4-95.4]) | 43/45 (95 [89.5-100]) |
| 38/40 (95 [83.1-99.4]) | 28/30 (93 [84.4-100]) |

*Including all patients for the analysis.
†Excluding 28 of 103 patients (27%) with only partial coronary tree coverage available.

I am a soldier, convinced that I am acting on behalf of soldiers. I believe that this war, upon which I entered as a war of defense and liberation, has now become a war of aggression and conquest. I believe that the purposes for which I and my fellow-soldiers entered upon this war should have been so clearly stated as to have made it impossible to change them, and that, had this been done, the objects which actuated us would now be attainable by negotiation.

—Siegfried Sassoon (1886-1967)